

**Natal Associated Asymmetry of Bony Structures of Craniovertebral Junction As the Probable Cause for Fixation of Vertebral Misalignment and Functional Instability of The Upper Cervical Vertebrae**

By Andrey V. Molodetskikh, Antonina P. Tishkova

In Russian the article was published in the Manual Therapy Journal

(ISSN 1684-6753), 2014 #2(54), 80 – 85.

## Abstract

The article presents the results of the analysis of X-ray craniovertebral junction points demonstrating regular failures in the form of asymmetry of bone structures of the area. We discuss here the causal relationship of these disorders with birth trauma of the cervical spine, dynamics thereof in the postpartum period leading to fixation of vertebral misalignment and functional instability of the upper cervical vertebrae which causes or exacerbates subluxation syndrome.

**Keywords:** birth trauma of the cervical spine, craniovertebral junction, atlas, axis, subluxation, misalignment retaining.

**Introduction:** In general practice, the etiological role of disturbances in the upper cervical spine and craniovertebral junction in the development of various pathological conditions is underestimated as a rule. Meanwhile, the prevalence of such disorders is high enough. Thus, according to A. Ratner (1978), X-ray signs of damage of the cervical spine were revealed in 86% of infants and older children. In most cases, a hidden natal damage to the cervical spine is not diagnosed, but still has a negative impact on child development and health status throughout life<sup>1-9</sup>. It is comforting yet that most attention is being given to this issue in recent times<sup>10-12</sup>.

At the heart of the negative impact of natal injuries of the upper cervical spine on the functions of the body is a neurotransmission failure in the brain stem as well as cerebral hemodynamics and liquor dynamics. The pathogenesis of these disorders is a multistage process including at least structural, trophic and irritative components. Among them partial occlusion of the spinal canal forming an irritative zone in close proximity to the brain stem and the violation of trophic process of nervous tissue<sup>7</sup> can be noted. Possible negative effects of disturbances in the upper cervical spine and craniovertebral junction are extremely diverse. Hence, the vertebral-basilar insufficiency syndrome (vertebrobasilar arterial system — G45.0 ICD-10), with all its polymorphism of clinical manifestations being just one example of such consequences. The result of chronic disorders in craniovertebral passage can be not only somatic but various psychiatric failures. Afferent disintegration<sup>13</sup> is considered as a functional mechanism for the development of mental disorders, especially during brain growth and development.

### The Purpose of the Study

Identification of certain consistent radiographic features of structural defects in craniovertebral junction.

### Materials and Methods

Patients of both genders between the ages of 9 to 66, who had been treated with various complaints by a therapist and/or neurologist and then sought for chiropractic care. Inclusion criteria were: patient compliance, as well as parents of those patients who have not attained the age of majority. Exclusion criteria were contraindications for radiography.

Transoral radiography was performed using *Philips Duo Diagnost* X-ray machine as follows: the patient sat near a vertical bar, the median plane of the head being perpendicular to the cassette's plane. Mouth opened as much as possible. The central beam was directed perpendicular to the plane of the tape along the median plane at the lower edge of the upper incisors. The radiographs demonstrated that against the background of open mouth foramen magnum, the lateral masses of C1, the body and the spinous process of C2 could be clearly seen.

180 radiographs were analyzed.

## The Results of the Study

The X-ray analysis revealed the asymmetry of the body and the articular surfaces of the atlas, axis and condyles of the occipital bone. In various combinations signs of asymmetry were found in the 136 radiographs (75.6%). The asymmetry of the atlas was manifested as follows: different height/width of the lateral masses of the atlas, the difference is the length of the contour of the articular surfaces of the right and left, the asymmetry of the shape and angle of the contour of the articular surfaces on the right and the left. The asymmetry of the articular surfaces of the axis appeared in the form of difference and angle of the contour to the right and to the left (subject to the absence of rotation). Signs of asymmetry of the condyles of the occipital bone were different angles and shape the contour of the articular surfaces of the right and left, the deviation from the horizontal imaginary line connecting the outermost distal points of both the condyles (numerical indicators — those of linear dimensions, angles — in the context of this study are not important. What is important is the very fact of asymmetry, which can be easily seen if the image is folded along the axis of an X-ray image of the spine). In almost all cases the asymmetry was combined with abnormal interposition of the upper cervical vertebrae and the condyles of the occipital bone in the joints (asymmetry of articular cavity, offset, turn and tilt of the atlas and/or axis) meaning the signs of vertebral misalignment (striking examples: Fig. 1—8).

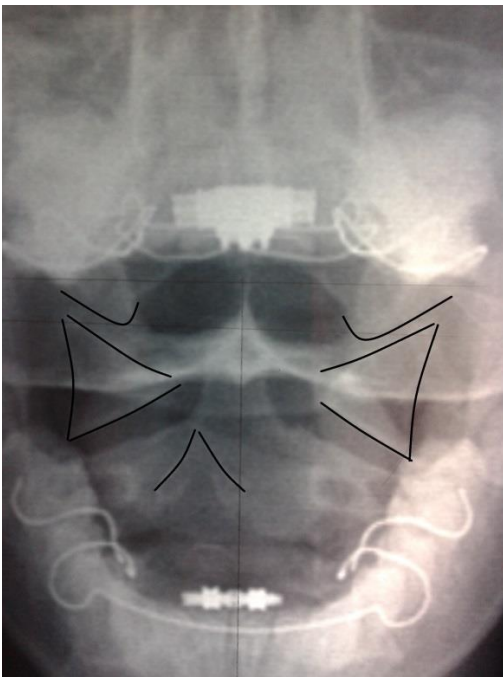


Fig. 1. Girl, 9 years old

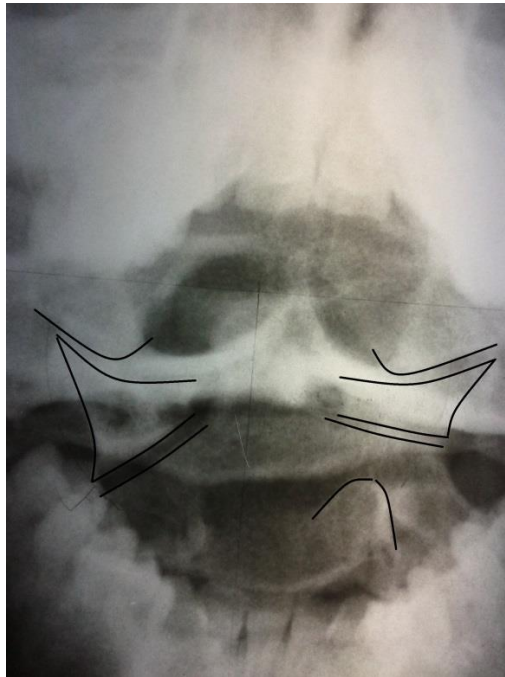


Fig. 2. Teenage girl, 16 years old

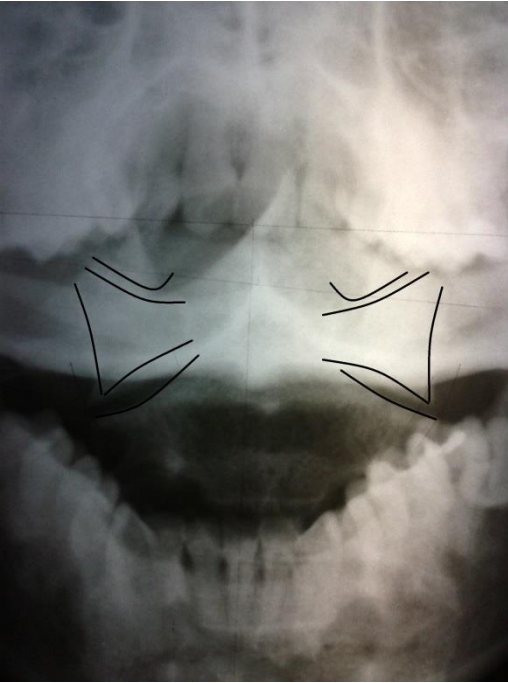


Fig. 3. Woman, 42 years old.

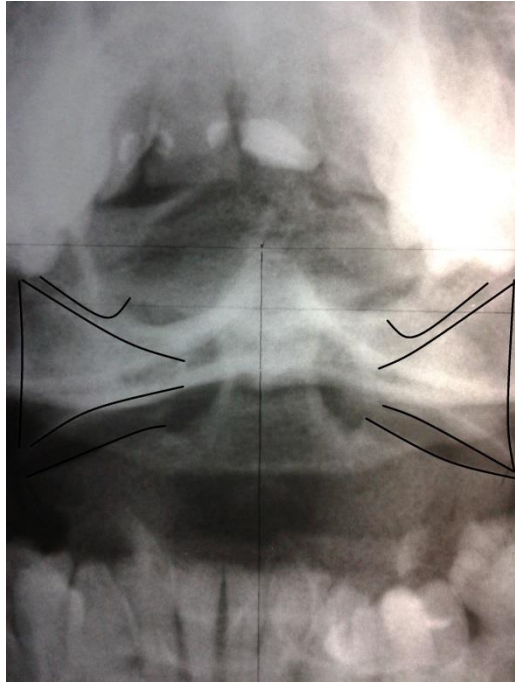


Fig. 4. Man, 42 years old.

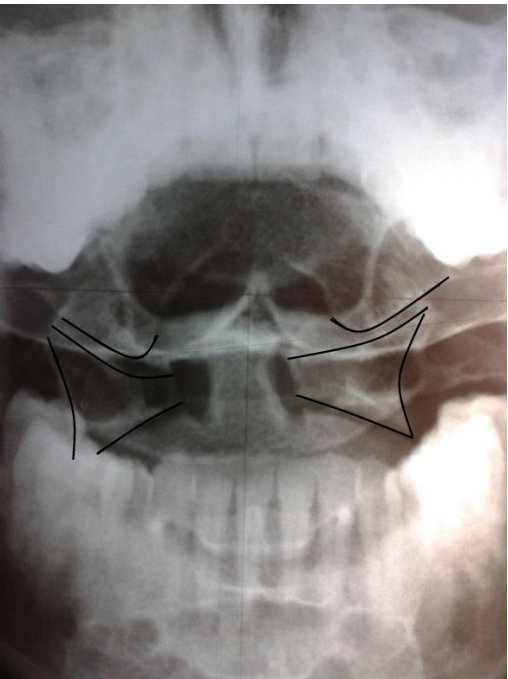


Fig. 5. Man, 32 years old.

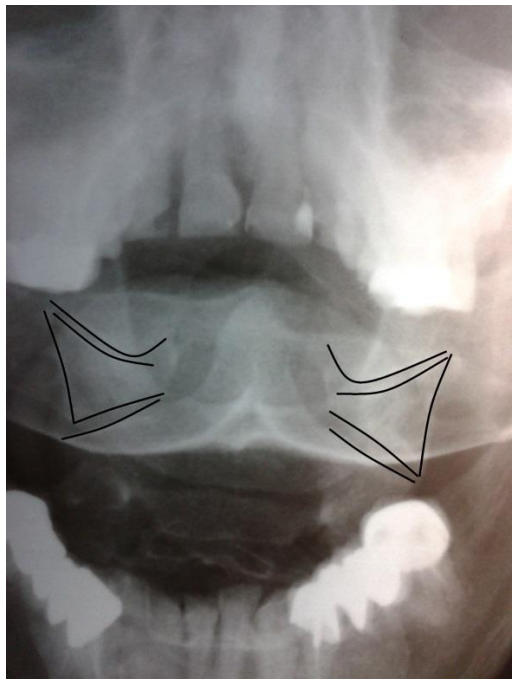


Fig. 6. Woman, 54 years old.

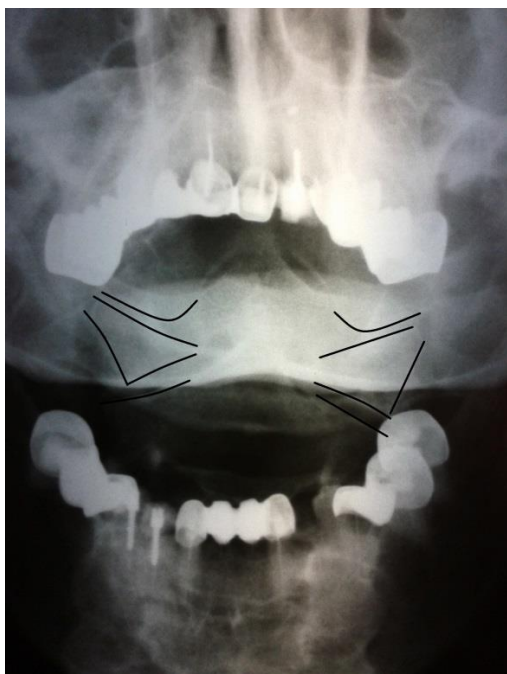

Fig. 7. Woman, 64 years old.

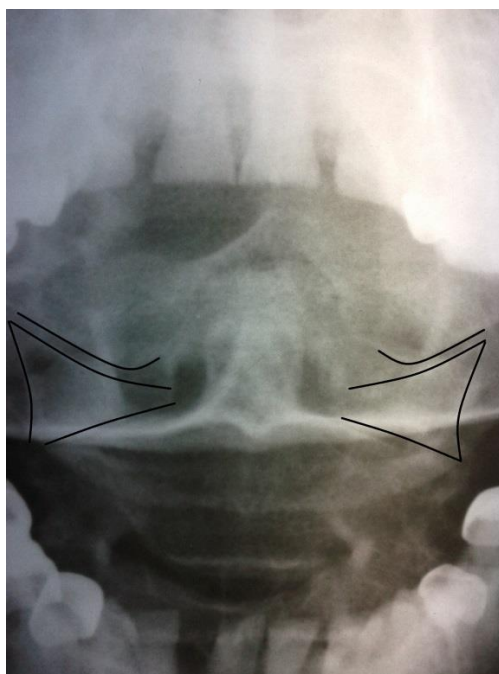


Fig. 8. Woman, 66 years old

Taken together, the number of X-ray images with the signs of certain disorders in craniovertebral junction (asymmetry, misalignment or a combination thereof) was 172 (95.6%). At the same time, medical history data related to postnatal clinically significant head and spine trauma, which theoretically could have been the cause of disorders in craniovertebral junction were received only in 11 (6.1%) patients studied.

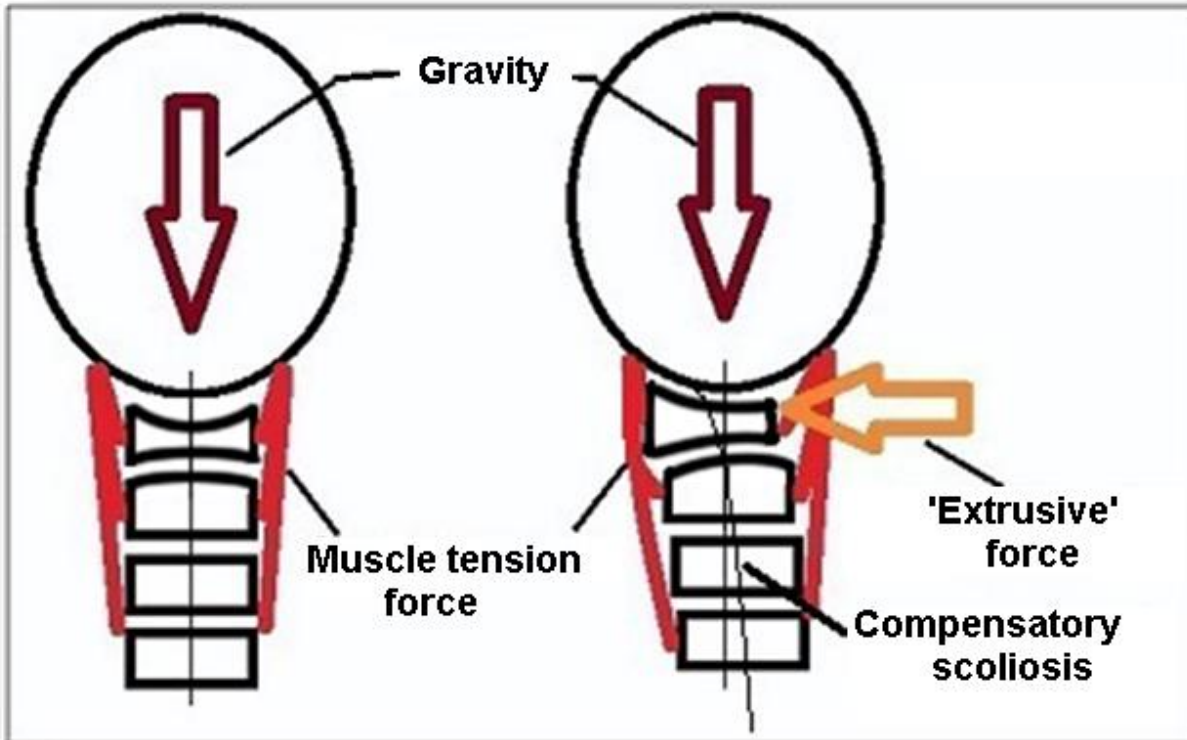
In view of the high incidence of birth injury of the cervical spine due to anthropological features, we can assume that the cause of offset of the upper cervical vertebrae in most cases is birth process as such.

It is necessary to give an explanation and make an eloquent quote from Claude Owen Lovejoy: "The difficulty of combining in the same pelvic structures of such diverse tasks as the effective operation of the hip joint while moving on two legs and the provision of adequate birth canal for a child with a big brain, however, remains unmastered, the birth process in humans being the one of the heaviest in the animal kingdom", and further, "childbirths remain difficult and painful process"<sup>14</sup>. Employees of the Institute of Developmental Physiology of the Russian Academy of Sciences G. Vershubskaya and A. Kozlov in their review article<sup>15</sup> indicate: "The internal dimensions of woman's pelvis are too small relative to a non-configured fetal head. But even configuration is unable to ensure safe passage of the fetus through the birth canal." It is interesting that "as opposed to a person, traumatic injuries in animals in childbirth are almost completely excluded, because the situation in parturition is very different, and an animal's head is never transverse on the birth canal being of large dimensions." (Neumarker, 1977, quoted as per A. Ratner<sup>7</sup>).

A vertebra dislocated as a result of birth trauma (apparently often this being the atlas) perceives an unbalanced load. In such conditions, during growth and maturation of the bony tissue the vertebral body is formed asymmetric. The same thing happens with the surrounding formations of the skull and the second cervical vertebra. Gradually, this leads to the misalignment **retaining**. Asymmetric vertebrae are permanently in a volatile, non-equilibrium state, which can be schematically seen in a figure below:

Norm:

Asymmetry causes subluxation:



Cranial articular surfaces of the atlas and the articular surfaces of condyles of the occipital bone in 3D space resemble segments of a conventional hemisphere. Hence, the atlas misalignment is its spiral dislocation (16) with an offset of axial load to the periphery of a joint-like atlanto-occipital articulation.

As a matter of fact and as such, the craniovertebral junction is a chronic pathogenic area. Acute or significant tension in one's neck (falls, bruises, physical stresses, nervous tensions and other functional changes in the body) is likely to decompensate that misalignment and therefore cause or exacerbate subluxation syndrome. Given the wide range of possible neurovascular effects caused by compression, irritation, ischemia of the nerve bundles carrying all somatic neuroregulation<sup>7, 17</sup>, decompensation of chronic subluxation may represent a specific mechanism for the implementation of the well-known fact that any excessive strength and/or duration thereof and stressful effects often lead to the emergence or worsening of diseases.

## Conclusions

1. Offset of the atlas and/or axis due to birth trauma of the cervical spine leads to an asymmetric load distribution on the specified vertebrae and the occipital condyles.
2. Under an unbalanced load, in the process of growth and development of bone tissue the vertebral bodies and adjacent skull formations are also formed asymmetrical. This leads to retaining of that misalignment and irreversible structural damage.
3. The physical overloads and stress factors can exacerbate misalignment and therefore cause or decompensate sUBLuxation due to a sudden or significant tension of the neck muscles.
4. In childhood it is necessary to correct the vertebral offset as early as possible, until there appear irreversible structural changes in the vertebrae.

In conclusion I would like to quote M. Gytner that perinatal damage to the nervous system is "the most common national disease" (Leningrad: Med-Giz 1945, quoted as per<sup>7</sup>). And once again we draw your attention to the importance and, at the same time, to a paradoxical clinical irrelevance of the long established fact indicating the high frequency of birth trauma of the cervical spine and central nervous system and its negative consequences for health. As likely as not, that it is the birth process traumatic in its nature and the subsequent formation of pathogenic area in craniovertebral junction cause specific human morbidity and virtually untreatability (meaning medication) of most chronic diseases.

## References

1. E.A. Morozova: Late Neurological Changes in Children Who Underwent Natal Trauma of the Cervical Spine: thesis. Candidate of medical sciences.— Kazan, 1993.
2. E.V. Myaukina: Natal Pathology of the Central Nervous System.— Petrozavodsk, 1999.
3. A.I. Borisova, L.G. Nissan, E.E. Stysina, N.N. Belyanina: Etiologic and Pathogenetic Factors of Craniovertebral Area Imbalances. *Journal of Neurology and Psychiatry* – 2000 – No. 4. – pp. 62– 64.
4. L.A. Plekhanov: Modern Presentation and Screening Diagnostics of Birth Injuries of the Spine and the Spinal Cord in Infants: Training Guidelines.— Chelyabinsk, 2003.
5. V.F. Prusakov, E.A. Morozov, V.I. Marulina, M.A. Utkuzova, M.V. Belousova, F.M. Zaykova: Perinatal Pathology of the Brain and Related Consequences. // *The Practice of Medicine*.— 2010.— No. 2 (10). <http://pmarchive.ru/>
6. A.Yu. Ratner: Birth Spinal Cord Injuries in Children.— Kazan, 1978.
7. A.Yu. Ratner: Neurology of Newborns: the Acute Phase and Late Complications. 4th edition — Moscow, 2008.
8. M.N. Stogov: Natal Associated Damage to the Upper Cervical Vertebrae (Clinical and Radiographic Comparison): thesis. Candidate of medical sciences — Kazan, 1989.
9. I.I. Sholomov: Birth Injury of the Cervical Spine and the Spinal Cord (Clinical Manifestations, Diagnosis, Treatment): Author's abstract: thesis. Candidate of medical sciences — Saint-Petersburg., 1995.
10. I.M. Lee, A.B. Sitel: Formation of the Musculoskeletal System in Children with Natal Craniocervical Trauma. // *Manual Therapy* — 2011— No. 3. — pp. 41—47.
11. I.M. Lee: Attention Deficit Syndrome in Children with Natal Craniocervical Trauma. // *Manual Therapy* — 2013 — No. 3.— pp.55—60.
12. A.I. Nebozhin et al.: Structure and Clinical Manifestations of Functional Biomechanical Disorders in Newborns and Infants with Neurological Disorders. // *Manual Therapy*.— 2013.— No. 4.— pp. 35— 39.
13. A.V. Molodetskikh: On Etiopathogenesis of Mental Disorders. // *Journal of Psychiatry and Psychology of Chuvashia*.— 2011.— No. 7.— pp. 81—89.
14. C.O. Lovejoy: Evolution of Rectified Mode of Transportation in Humans. // *In the World of Science. Scientific American* — 1989. — No. 1. — pp. 45—56.
15. G.G. Vershubskaya, A.I. Kozlov: Approaches to the Study of a Newborn Body Size: Scientific Schools and 'Unsolved Brain-Teasers'. Message 1: The Contribution of Morphology, Anthropology and Genetics. *New Research almanac. Institute of Developmental Physiology, Russian Academy of Sciences (Moscow)*. — 2009. — No. 1. – pp. 51—57.
16. B.J. Palmer: The Subluxation Specific — The Adjustment Specific. // *Special Edition, 1991, Volume 18*.
17. R.C. Schafer: Basic Principles of Chiropractic: The Neuroscience Foundations of Clinical Practice. *American Chiropractic Association, 1990*.

## Reprint Address

119571, Leninskiy prospect, 156 - 228, Moscow, Russia.  
To: Andrey V. Molodetskikh.